

# Aortic Valve Leaflet Perforation after Mitral Valve Repair

**Aboelnasr M.<sup>1</sup>, Rohn V.<sup>2</sup>**

<sup>1</sup>Department of Cardiothoracic Surgery, Tanta University Hospital, Tanta, Egypt;

<sup>2</sup>2<sup>nd</sup> Department of Surgery – Department of Cardiovascular Surgery, First Faculty of Medicine, Charles University in Prague and General University Hospital in Prague, Prague, Czech Republic

Received December 9, 2012; Accepted August 14, 2013.

**Key words:** Aortic regurgitation – Aortic valve perforation – Mitral valve repair

**Abstract:** A 32-year-old patient with symptomatic severe aortic regurge, 6 weeks after mitral valve repair, was admitted for aortic valve surgery. No preoperative clinical data consistent with infective endocarditis could be detected. Preoperative transthoracic echocardiography showed aortic leaflet perforation affecting non coronary cusp. During operation, leaflet perforation was detected and closed completely with autologous pericardial patch. No vegetations or abscess could be seen during operation. Iatrogenic aetiology of leaflet perforation after mitral repair was suspected in this case. Recognition of this complication will help in avoiding it during mitral valve surgery and expecting it as a possible complication during intraoperative transesophageal echocardiography.

**Mailing Address:** Vilém Rohn, MD., PhD., 2<sup>nd</sup> Department of Surgery – Department of Cardiovascular Surgery, First Faculty of Medicine, Charles University in Prague and General University Hospital in Prague, U nemocnice 2, 128 00 Prague 2, Czech Republic; Phone: +420 224 962 797; Fax: +420 224 922 695; e-mail: vilem.rohn@seznam.cz

### Introduction

Infective endocarditis is a common cause for aortic leaflet perforation (Fowler et al., 1967), however; occurrence of aortic valve perforation after cardiac operation may raise suspicion for iatrogenic cause.

Despite cardiac surgery through transaortic approach as a repair of aortic valve and septal myotomy or myectomy is expected to be associated with aortic valve leaflet perforation (Mohr et al., 1989), few reports are concerned with the incidence of aortic valve leaflet perforation after cardiac operations performed in the vicinity of aortic valve and not through transaortic approach such as mitral valve surgery, closure of membranous ventricular septal defect and atrial septal defect repair (Wada et al., 1979; Rey et al., 1991; Rother et al., 2000).

Here, we present a case of severe aortic regurgitation due to aortic valve leaflet perforation after mitral valve repair.

### Case report

A 32-years-old male patient with hypertension and hyperlipidaemia presented to our department with exertional dyspnea and NYHA class II. Early diastolic murmur was audible on second aortic area. The patient had history of mitral valve repair 6 weeks ago due to severe myxomatous mitral regurge. During that operation,

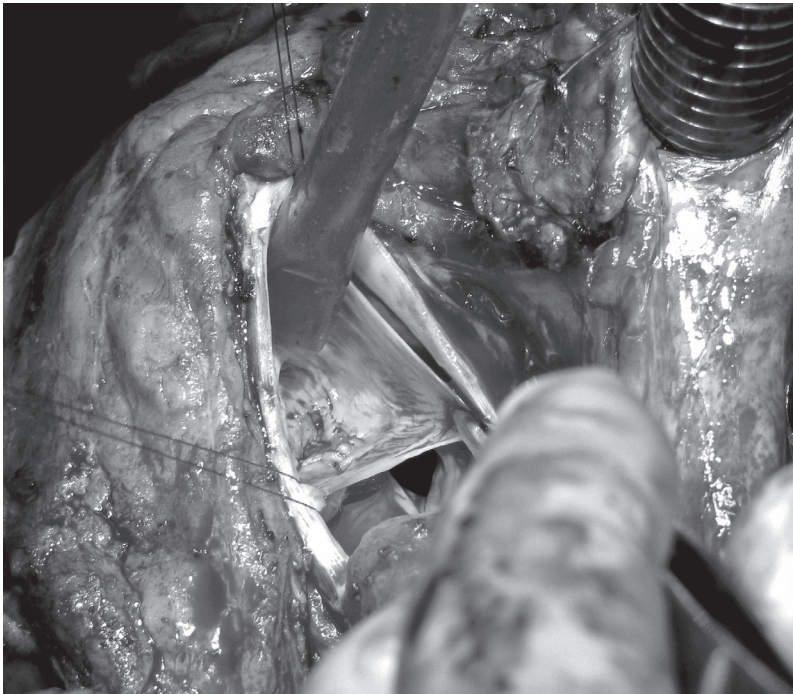


Figure 1 – Complete closure of perforation with autologous pericardial patch.

quadrangular resection of P2 segment with sliding plasty was done together with triangular resection of A2 and insertion of CE ring 30 mm. The patient had uneventful weaning from cardiopulmonary bypass with competent mitral valve as detected by trans-oesophageal echocardiographic examination (TEE). Postoperative ECHO performed six days after operation revealed grade II aortic regurge with 6 mm jet based on non coronary cusp of aortic valve. The patient discharged from the hospital for follow up of aortic regurge. After admission of the patient, follow up echo showed progression of degree of aortic regurge reaching grade IV. The patient was scheduled for aortic valve surgery. To accurately determine the severity and mechanism of aortic regurge, intraoperative TEE was performed that showed severe aortic regurge originating from non coronary cusp by colour examination in short axis view. Under general anaesthesia, redo median sternotomy was done with releasing of pericardial adhesions and institution of standard cardiopulmonary bypass under mild hypothermia. Aortotomy was performed and antegrade blood cardioplegic solution was delivered through both coronary ostia. Aortic valve leaflets were inspected with gentle grasping of each cusp. No signs of infective endocarditis as abscess or vegetation could be detected. Perforation in non coronary cusp 1×0.5 cm was found. Other cusps were normal. Defect edges were delineated and debrided gently and then autologous pericardial patch fixed with 0.6% gluteraldehyde was used in closing the perforation by continuous suture (Figure 1). The patient was then successfully weaned from bypass and intraoperative TEE showed well closed defect with disappearance of regurgitant jet. The postoperative course was thereafter uneventful.

## Discussion

Severe aortic regurgitation is an infrequent complication of mitral valve repair (Carpentier et al., 1980). Review of cardiac skeleton will be helpful to understand the relationship between mitral valve surgery and aortic valve leaflet perforation. The aortic valve is the cornerstone of cardiac skeleton with its centrally located position between the other 3 valves. Fibrous extension of aortic valve touches the annuli of mitral and tricuspid valve. Right and left fibrous trigones also share in formation of cardiac skeleton and provide direct continuity between mitral and aortic valves and thus surgical repair of one valve will alter significantly the geometry of the other (Malouf et al., 2005). In this case report, the cause of aortic regurge was leaflet perforation however other mechanisms were explained in other literatures. Ducharme et al. (1999) reported a case of severe aortic regurge after mitral valve repair caused by the tension of mitral ring on aortic annulus and the regurge was corrected during the operation by releasing 3 sutures on the mitral annular ring. Mehta and Hunsaker (2007) reported a case of intraoperative severe aortic regurge due to inadvertently placed suture through aortic left coronary cusp during mitral valve replacement and the patient was treated with aortic valve replacement.

In this case study, the diagnosis of aortic regurgitation was delayed till 6 days postoperative and 2D TEE did not discover it during operation. Intraoperative intervals between mitral valve surgery and the diagnosis of aortic regurgitation are variable between early intraoperative diagnosis (Hill et al., 1997) or late even after 6 years (Lee et al., 1996). Three dimensional TEE was recently used for proper detection of iatrogenic aortic valve leaflet perforation with high accuracy (Dreyfus et al., 2011).

During operation, we found that perforation affected non coronary cusp and this is in accordance with the study by Hill et al. (1997) who concluded that any leaflet could be perforated depending on procedure performed, and mitral valve surgery usually puts non coronary and left coronary cusp at risk.

As infective endocarditis is the commonest cause of aortic leaflet perforation (Ballal et al., 1991), it should be taken into consideration in any patient during preoperative evaluation and during intraoperative evaluation. In this case, no signs of endocarditis could be detected either through preoperative investigations as the patient was afebrile with negative blood culture or during intraoperative valve inspection.

To conclude, aortic valve leaflet perforation after mitral valve surgery is rare but may be underreported event after surgery. Increased awareness of this complication will help in avoiding it during surgery. It is also important to expect it as a possible existence during performing TEE after separation from bypass so that iatrogenic surgical complications may be diagnosed in a timely fashion.

## References

- Ballal, R. S., Mahan, E. F. III., Nanda, N. C. (1991) Aortic and mitral valve perforation: Diagnosis by transesophageal echocardiography and Doppler color flow imaging. *Am. Heart J.* **121**, 214–217.
- Carpentier, A., Chauvaud, S., Fabiani, J. N., Deloche, A., Relland, J., Lessana, A., D'Allaines, C., Blondeau, P., Piwnica, A., Dubost, C. (1980) Reconstructive surgery of mitral valve incompetence: ten-year appraisal. *J. Thorac. Cardiovasc. Surg.* **79(3)**, 338–348.
- Dreyfus, J., Feldman, L. J., Lepage, L., Brochet, E., Berjeb, N., Lung, B., Vahanian, A., Messika-Zeitoun, D. (2011) Iatrogenic aortic valve perforation assessed using three-dimensional transoesophageal echocardiography. *Arch. Cardiovasc. Dis.* **104(8–9)**, 486–487.
- Ducharme, A., Courval, J. F., Dore, A., Leclerc, Y., Tardif, J. C. (1999) Severe aortic regurgitation immediately after mitral valve annuloplasty. *Ann. Thorac. Surg.* **67(5)**, 1487–1489.
- Fowler, N. O., Hamburger, M. H., Bove, K. E. (1967) Aortic valve perforation. *Am. J. Med.* **42**, 539–546.
- Hill, A. C., Bansal, R. C., Razzouk, A. J., Liu, M., Bailey, L. L., Gundry, S. R. (1997) Echocardiographic recognition of iatrogenic aortic valve leaflet perforation. *Ann. Thorac. Surg.* **64(3)**, 684–689.
- Lee, A. P., Walley, V. M., Ascah, K. J., Veinot, J. P., Davies, R. A., Keon, W. J. (1996) A fenestrated aortic valve contributing to iatrogenic aortic insufficiency post mitral valve replacement. *Cardiovasc. Pathol.* **5(2)**, 81–83.
- Malouf, J. F., Edwards, W. D., Tajik, A. J., Seward, J. B. (2005) Functional anatomy of the heart. In: *Hurst's the Heart*, 11<sup>th</sup> Edition, eds. Fuster, V., Alexander, R. W., O'Rourke, R. A., Roberts, R., King, S. B., Wellens, H. J. J., pp. 45–82, McGraw-Hill, New York.

- Mehta, A. R., Hunsaker, R. (2007) Iatrogenic aortic incompetence after mitral valve replacement. *J. Cardiothorac. Vasc. Anesth.* **21**(2), 276–278.
- Mohr, R., Schaff, H. V., Puga, F. J., Danielson, G. K. (1989) Results of operation for hypertrophic obstructive cardiomyopathy in children and adults less than 40 years of age. *Circulation* **80**, 191–196 (Suppl. 1).
- Rey, C., Vaksman, G., Brevière, G. M., Dupuis, F. C. (1991) L'insuffisance aortique: une complication méconnue de la fermeture chirurgicale de la communication interauriculaire ostium primum. *Arch. Mal. Coeur Vaiss.* **84**, 627–631.
- Rother, A., Smith, B., Adams, D. H., Collard, C. D. (2000) TEE diagnosis of acute aortic valve insufficiency after mitral valve repair. *Anesth. Analg.* **91**, 499–500.
- Wada, J., Yokoyama, M., Imai, Y., Momma, K., Takao, A. (1979) Hemolysis due to aortic insufficiency following closure of ventricular septal defect. *Int. Surg.* **64**, 53–56.