

# Attenuated Type of Asphyxiating Thoracic Dysplasia due to Mutations in *DYNC2H1* Gene

**Anna Čechová<sup>1</sup>, Alice Baxová<sup>2</sup>, Jiří Zeman<sup>1</sup>, Lukáš Lambert<sup>3</sup>, Tomáš Honzík<sup>1</sup>, Alena Leiská<sup>3</sup>, Václav Čunát<sup>4</sup>, Markéta Tesařová<sup>1</sup>**

<sup>1</sup>Department of Pediatrics and Adolescent Medicine, First Faculty of Medicine, Charles University and General University Hospital in Prague, Prague, Czech Republic;

<sup>2</sup>Institute of Biology and Medical Genetics, First Faculty of Medicine, Charles University and General University Hospital in Prague, Prague, Czech Republic;

<sup>3</sup>Department of Radiology, First Faculty of Medicine, Charles University and General University Hospital in Prague, Prague, Czech Republic;

<sup>4</sup>The Institute for the Care of Mother and Child, Prague, Czech Republic

Received July 4, 2019; Accepted December 1, 2019.

**Key words:** Asphyxiating thoracic dysplasia – Chest circumference – *DYNC2H1* gene

**Abstract:** Asphyxiating thoracic dysplasia (ATD) represents a heterogeneous group of skeletal dysplasias with short ribs, narrow chest and reduced thoracic capacity. Mutations in several genes including *IFT80*, *DYNC2H1*, *TTC21B* and *WDR19* have been found in patients with ATD. Both severe and milder course of the disease were described in correlation with secondary involvement of lung's function. Two children with attenuated form of ATD are described. Their anthropometric parameters for birth weight, length and head circumference were normal but narrow thorax was observed in both of them in early infancy with chest circumference < –3 SD (standard deviation) in comparison to age related controls. The postnatal adaptation and development of both children was uneventful except for mild tachypnoea in one of them which persisted till the age of 6 months. In both children, radiographs

*This study was supported by projects of Ministry of Education, Youth, and Sports of the Czech Republic (PROGRES Q32/LF2) and Ministry of Health of the Czech Republic (RVO-VFN 64165/2012).*

**Mailing Address:** Ing. Markéta Tesařová, PhD., Department of Pediatrics and Adolescent Medicine, First Faculty of Medicine, Charles University and General University Hospital in Prague, Ke Karlovu 2, 128 08 Prague 2, Czech Republic; Phone: +420 224 967 748; e-mail: marketa.tesarova@lf1.cuni.cz

revealed narrow upper half of the chest with shorter ribs and atypical configuration of pelvis with horizontally running acetabula and coarse internal edges typical for ATD. Molecular analyses using whole exome sequencing in one family revealed that the patient is compound heterozygote in *DYNC2H1* gene for a frame-shift mutation c.4458delT resulting in premature stop-codon p.Phe1486Leufs\*11 and a missense mutation c.9044A>G (p.Asp3015Gly). The second family refused the DNA analysis. Regular monitoring of anthropometric parameters during childhood is of big importance both in health and disease. In addition, measurement of the chest circumference should be included, at least at birth and during infancy.

## Introduction

Asphyxiating thoracic dysplasia (ATD, Jeune syndrome) is a rare skeletal disease belonging to the large group of ciliopathies, disorders with primary impairment of cilia involved in the transduction of signals in the hedgehog pathway that is especially important in skeletal development (Dagoneau et al., 2009; Huber and Cormier-Daire, 2012).

On the molecular level, ATD represents a heterogeneous group of genetic disorders with mutations in several genes including *IFT80*, *DYNC2H1*, *TTC21B* and *WDR19* (Baujart et al., 2013). On the clinical level, ATD is characterized by short ribs resulting in narrow chest and reduced thoracic capacity, short long bones, inconstant polydactyly, and trident acetabular roof sometimes accompanied by renal, liver and retinal disease (Dagoneau et al., 2009). The course of the disease and the prognosis depend on the severity of ribs shortening with the residual lung function, recurrent lung infections and secondary heart problems (Emiralioglu et al., 2018). Both severe and attenuated forms of ATD were described, but the phenotype may differ even between siblings with the identical mutation in *DYNC2H1* suggesting the impact of some modifier alleles or epigenetic factors (Schmidts et al., 2013a).

We report the results of clinical and radiologic analyses in two children with attenuated type of asphyxiating thoracic dysplasia, in one of them due to mutations in *DYNC2H1*.

## Methods

DNA was extracted from blood samples by Gentra PureGene Blood Kit (Qiagen, USA). Exome sequencing was performed using 1 µg of DNA from patient 1 and both of his parents. For DNA enrichment of barcoded DNA libraries were used SeqCap EZ MedExome Target Enrichment Kit (Roche, USA) according to the manufacturer's protocol. The Illumina HiSeq 2500 system at the Genomic facility in University Hospital Motol was used for DNA sequencing of the captured barcoded DNA library. The resulting FASTQ files were aligned to the Human Genome Reference (hg19) using Novoalign (3.02.10) and processed as described previously (Chaloupka et al., 2018). Mutation identified in *DYNC2H1* (ENSG00000187240, ENST00000398093) was confirmed by Sanger sequencing. Anthropometric

parameters in affected children were compared to large nation-wide anthropological survey of Czech children (Vignerová et al., 2006).

### Ethics

The study was approved by the Ethics Committee of the General University Hospital in Prague and was conducted in agreement with institutional guidelines.

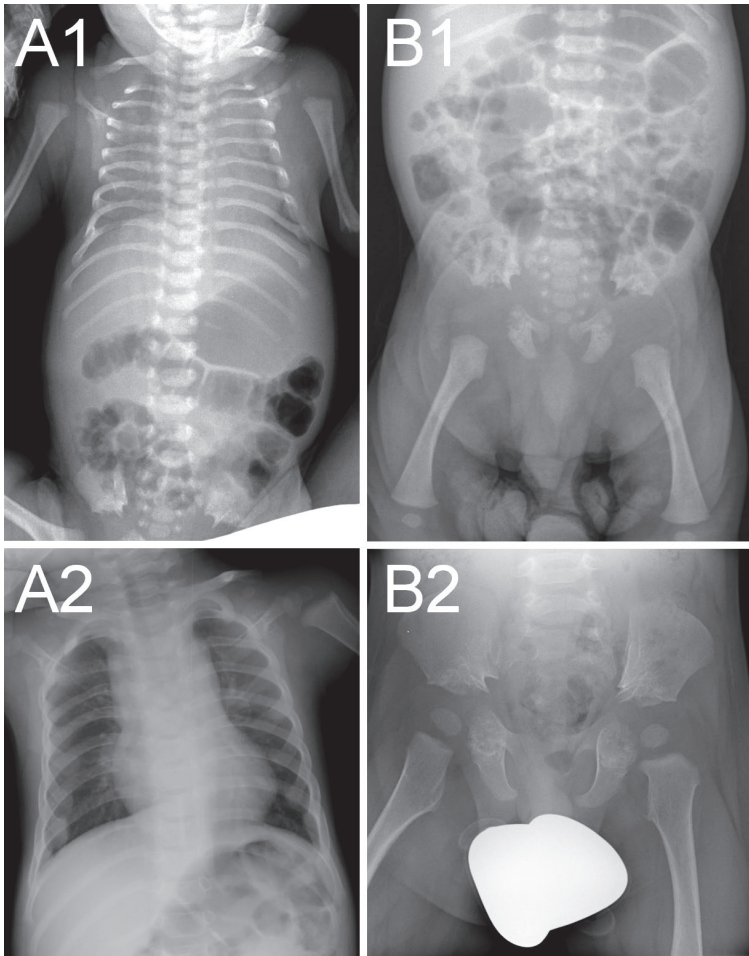


Figure 1 – Radiographs of the chest, pelvis, and hip joints in the boy (patient 1) with asphyxiating thoracic dysplasia due to heterozygous mutations *c.4458delT (p.Phe1486Leufs\*11)* and *c.9044A>G (p.Asp3015Gly)* in *DYNC2H1* gene at the age of 10 days (A1, B1) and 6 months (A2, B2). The rib cage is narrowed and elongated, ribs are shortened, running horizontally, their anterior ends are widened. The collar bones are positioned higher (A1, A2). The pelvis is dysplastic, iliac bones rounded, acetabular roofs are horizontal with pointed medial margins (B1, B2). The sciatic and pubic bones are shortened, sturdy with uneven widening at their junction. Both femoral necks are sturdy. Femoral heads have normal appearance and position, and there is a mild medial bowing of the diaphysis of both femurs.

In members of family 1, written informed consent for molecular analyses was obtained. The families have agreed with use of the results including relevant clinical data and photographs for publication.

### Patient 1

The parents, grandparents and older sister are healthy. The boy was born at term in the 40<sup>th</sup> week of gestation with birth weight 3,230 g (40<sup>th</sup> percentile), length 48 cm (10<sup>th</sup> percentile), head circumference 34 cm (35<sup>th</sup> percentile) and chest circumference 30.9 cm (−1.4 SD – standard deviation, gestation related controls 33.4±1.9). The postnatal adaptation was uneventful except mild tachypnoea which persisted till the age of 6 months and was explained by boy's narrow thorax. Radiographs of the chest and pelvic girdle suggesting asphyxiating thoracic dysplasia are shown in Figure 1. At the age of 10 months (Figure 2), the boy had weight 8,000 g (8<sup>th</sup> percentile), length 70 cm (10<sup>th</sup> percentile), head circumference 45 cm (25<sup>th</sup> percentile) and chest circumference 40.5 cm (−3.2 SD, age related controls 48.1±2.4). At the age of 18 months, his weight was 10.5 kg (20<sup>th</sup> percentile), length 78.5 cm (10<sup>th</sup> percentile), head circumference 47 cm (25<sup>th</sup> percentile) and chest circumference 43.5 cm (−3.3 SD, age related controls 50.0±1.8). His mental and motor development corresponded to his age and he had no tachypnoea or any other respiratory or heart problems including normal echocardiography.

### Patient 2

The parents and grandparents are healthy. The girl was born in term, but prenatal sonography in the second trimester revealed a disproportionate stature with some shortening of both legs. Her birth weight was 3,300 g (55<sup>th</sup> percentile), length

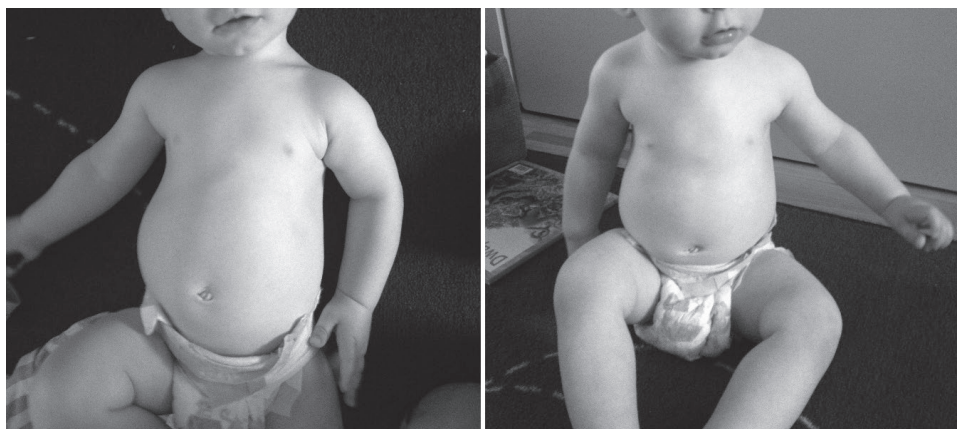

Figure 2 – The 10-months old boy (patient 1) with asphyxiating thoracic dysplasia and narrow chest circumference 40.5 cm (age related controls 46.7 cm) due to heterozygous mutations *c.4458delT* (*p.Phe1486Leufs\*11*) and *c.9044A>G* (*p.Asp3015Gly*) in *DYNC2H1* gene.

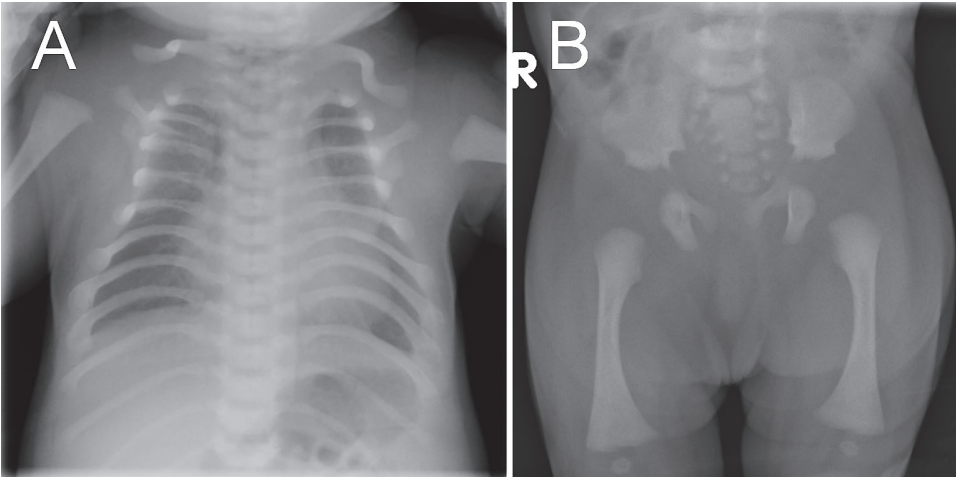


Figure 3 – Radiograph of the chest (A) and pelvis (B) in a 2-months-old girl (patient 2) with asphyxiating thoracic dysplasia. The rib cage is narrow and elongated, ribs are short and horizontal, their anterior ends are widened. The collar bones are positioned higher. The pelvis is dysplastic, iliac bones rounded; acetabular roofs are horizontal with pointed medial margins. The sciatic and pubic bones are shortened, sturdy with uneven widening at their junction. Both femoral necks are sturdy. Femoral heads have normal appearance and position, and there is a mild medial bowing of the diaphysis of both femurs.

47 cm (6.6<sup>th</sup> percentile) and head circumference 34 cm (40<sup>th</sup> percentile). Postnatal adaptation was uneventful, and she gained her weight properly. The results of neurologic investigation and sonography of the brain and kidney were normal. At the age of 2 months, her weight was 4,170 g (30<sup>th</sup> percentile), length 53.5 cm (14<sup>th</sup> percentile), head circumference 36.5 cm (12<sup>th</sup> percentile) but the thorax was narrow with chest circumference 33 cm (–3.1 SD, age related controls 39.0±1.6). Radiographs of the chest and pelvic girdle in the girl were compatible with the diagnosis of asphyxiating thoracic dysplasia (Figure 3). The parents refused the diagnostics on a molecular level. According to the phone contact with the mother, the motor and mental development of the girl is appropriate to her age and she has no respiratory problems.

### Molecular analyses

The molecular analyses in the family 1 using whole exome sequencing revealed that the boy is compound heterozygote for two variants in *DYNC2H1* gene: the frame-shift mutation c.4458delT resulting in premature stop-codon p.Phe1486Leufs\*11 and mutation c.9044A>G (p.Asp3015Gly). Both parents are heterozygotes for one mutation. The maternally inherited mutation c.4458delT in exon 29 has been previously found in patient with short-rib polydactyly syndrome type III (Verma-Naumoff syndrome, MIM# 263510) (Zhang et al., 2018). The second paternally

inherited mutation c.9044A>G in exon 57 has been previously found in several patients with ATD (Dagoneau et al., 2009; Schmidts et al., 2013a).

## Discussion

Ciliary defects arising from mutations in genes encoding ciliary proteins lead to complex developmental disorders in human and other vertebrates, termed ciliopathies (Schmidts et al., 2013b). One type of ciliopathies with skeletal involvement and short ribs with or without polydactyly is represented by a heterogeneous group of diseases including asphyxiating thoracic dysplasia (ATD, Jeune syndrome), Verma-Naumoff syndrome (SRP type III), Majewski syndrome (SRP type II), Ellis-van Creveld syndrome (EVC), the Sensenbrenner syndrome, and Weyers acrofacial dysostosis (Huber and Cormier-Daire, 2012).

Molecular analyses in children with Jeune syndrome revealed mutations in several genes including *DYNC2H1* encoding the cytoplasmic dynein 2 heavy chain 1 involved in the generation and maintenance of cilia (Dagoneau et al., 2009) or genes involved in intraflagellar transport *IFT80*, *IFT122*, *IFT43*, *WDR35*, *WDR19*, *TTC21B* as well as in genes responsible for the basal bodies *NEK1*, *EVC* and *EVC2* (Huber and Cormier-Daire, 2012). Especially mutations in *DYNC2H1* seem to be the major gene responsible for ATD. For example, in the group of 53 patients with ATD including 23 patients and 30 fetuses from 39 families, mutations in *DYNC2H1* was found in 59% of cases (Baujat et al., 2013). Also in one of our patients, mutations in *DYNC2H1* was found including a frame-shift mutation c.4458delT resulting in premature stop-codon p.Phe1486Leufs\*11 (Zhang et al., 2018) and a missense mutation c.9044A>G (p.Asp3015Gly) (Dagoneau et al., 2009; Schmidts et al., 2013a). The parents of the second child with Jeune syndrome from our centre did not admit any eventual health problems in their child and did not agreed with molecular analysis.

Both our children with Jeune syndrome have a mild form of the disease. They are clinically well regardless of very narrow thorax with narrow chest circumference < 3 SD in comparison to healthy age-related controls, but neither of them had any acute severe pulmonary infection, so far.

## Conclusion

Regular monitoring of the weight, length and head circumference during childhood is very important both in health and disease. In addition, measurement of the chest circumference should be included, at least at birth and during infancy.

## References

- Baujat, G., Huber, C., El Hokayem, J., Caumes, R., Do Ngoc Thanh, C., David, A., Delezoide, A. L., Dieux-Coeslier, A., Estournet, B., Francannet, C., Kayirangwa, H., Lacaille, F., Le Bourgeois, M., Martinovic, J., Salomon, R., Sigaudy, S., Malan, V., Munnich, A., Le Merrer, M., Le Quan Sang, K. H., Cormier-Daire, V. (2013) Asphyxiating thoracic dysplasia: Clinical and molecular review of 39 families. *J. Med. Genet.* **50**, 91–98.

- Chaloupka, A., Piherova, L., Grochova, I., Binova, J., Krejci, J., Spinarova, L., Stranecky, V., Kmoch, S., Kubanek, M. (2018) Genetic architecture of recent-onset dilated cardiomyopathy in Moravian region assessed by whole-exome sequencing and its clinical correlates. *Biomed. Pap. Med. Fac. Univ. Palacky Olomouc Czech Repub.* (Epub ahead of print)
- Dagoneau, N., Goulet, M., Genevieve, D., Sznajder, Y., Martinovic, J., Smithson, S., Huber, C., Baujat, G., Flori, E., Tecco, L., Cavalcanti, D., Delezoide, A. L., Serre, V., Le Merrer, M., Munnich, A., Cormier-Daire, V. (2009) DYNC2H1 mutations cause asphyxiating thoracic dystrophy and short rib-polydactyly syndrome, type III. *Am. J. Hum. Genet.* **84**, 706–711.
- Emiralioglu, N., Wallmeier, J., Olbrich, H., Omran, H., Ozcelik, U. (2018) DYNC2H1 mutation causes Jeune syndrome and recurrent lung infections associated with ciliopathy. *Clin. Respir. J.* **12**, 1017–1020.
- Huber, C., Cormier-Daire, V. (2012) Ciliary disorder of the skeleton. *Am. J. Med. Genet. C Semin. Med. Genet.* **160C**, 165–174.
- Schmidts, M., Arts, H. H., Bongers, E. M., Yap, Z., Oud, M. M., Antony, D., Duijkers, L., Emes, R. D., Stalker, J., Yntema, J. B., Plagnol, V., Hoischen, A., Gilissen, C., Forsythe, E., Lausch, E., Veltman, J. A., Roeleveld, N., Superti-Furga, A., Kutkowska-Kazmierczak, A., Kamsteeg, E. J., Elcioglu, N., van Maarle, M. C., Graul-Neumann, L. M., Devriendt, K., Smithson, S. F., Wellesley, D., Verbeek, N. E., Hennekam, R. C., Kayserili, H., Scambler, P. J., Beales, P. L., UK10K, Knoers, N. V., Roepman, R., Mitchison, H. M. (2013a) Exome sequencing identifies DYNC2H1 mutations as a common cause of asphyxiating thoracic dystrophy (Jeune syndrome) without major polydactyly, renal or retinal involvement. *J. Med. Genet.* **50**, 309–323.
- Schmidts, M., Vodopiutz, J., Christou-Savina, S., Cortes, C. R., McInerney-Leo, A. M., Emes, R. D., Arts, H. H., Tuysuz, B., D'Silva, J., Leo, P. J., Giles, T. C., Oud, M. M., Harris, J. A., Koopmans, M., Marshall, M., Elcioglu, N., Kuechler, A., Bockenhauer, D., Moore, A. T., Wilson, L. C., Janecke, A. R., Hurles, M. E., Emmet, W., Gardiner, B., Streubel, B., Dopita, B., Zankl, A., Kayserili, H., Scambler, P. J., Brown, M. A., Beales, P. L., Wicking, C., UK10K, Duncan, E. L., Mitchison, H. M. (2013b) Mutations in the gene encoding IFT dynein complex component WDR34 cause Jeune asphyxiating thoracic dystrophy. *Am. J. Hum. Genet.* **93**, 932–944.
- Vignerová, J., Riedlová, J., Bláha, P., Kobzová, J., Krejčovský, L., Brabec, M., Hrušková, M. (2006) *6<sup>th</sup> Nation-wide Anthropological Survey of Children and Adolescents 2001, Czech Republic.* Faculty of Sciences, Charles University, and the National Institute of Public Health, Prague. (in Czech)
- Zhang, W., Taylor, S. P., Ennis, H. A., Forlenza, K. N., Duran, I., Li, B., Sanchez, J. A. O., Nevarez, L., Nickerson, D. A., Bamshad, M., University of Washington Center for Mendelian Genomics, Lachman, R. S., Krakow, D., Cohn, D. H. (2018) Expanding the genetic architecture and phenotypic spectrum in the skeletal ciliopathies. *Hum. Mutat.* **39**, 152–166.