

# Accessory Flexor Muscle of Forearm – A Rare Variant – Embryological and Clinical Prospect

Kamalesh Saravanan<sup>1</sup>, Rajesh Kumar<sup>2</sup>, Dibakar Borthakur<sup>1</sup>,  
Harisha Kusuma<sup>1</sup>, Seema Singh<sup>1</sup>

<sup>1</sup> Department of Anatomy, All India Institute of Medical Sciences, New Delhi, India;

<sup>2</sup> Department of Anatomy, All India Institute of Medical Sciences, Patna, India

Received July 24, 2024; Accepted October 29, 2024.

**Key words:** Flexor muscle of forearm – Accessory muscle of forearm – Flexor carpi ulnaris – Palmaris longus – Anatomical variation

**Abstract:** Several muscle variations have been observed in flexor aspect of forearm which can hamper normal functioning of hand or may remain silent. One such unreported variation has been described in this report. An accessory muscle in the left forearm was found involving flexor carpi ulnaris (FCU) and palmaris longus (PL). This muscle was originating from the distal part of both FCU and PL through a slip from each tendon. After merging, it passed above the ulnar nerve and artery in the roof of Guyon's canal. This type of variation can cause neurovascular compression and can also mimic soft tissue mass, tumour or neuroma and can be misdiagnosed. Knowledge about this type of variation is important in cases of neurovascular decompression, forearm, and hand surgeries and these can be utilized in tendon transfer or free muscle flap for reconstruction purposes.

**Mailing Address:** Dr. Seema Singh, Department of Anatomy, Convergence block,  
All India Institute of Medical Sciences, Ansari Nagar, New Delhi, 110029, India;  
e-mail: seemahkg@gmail.com

<https://doi.org/10.14712/23362936.2024.32>

© 2024 The Authors. This is an open-access article distributed under the terms of the Creative Commons Attribution License (<http://creativecommons.org/licenses/by/4.0>).

## Introduction

Variations in muscles of flexor compartment of forearm can hamper normal functioning of forearm and hand. Accessory or supernumerary muscles of forearm are usually asymptomatic and usually identified incidentally during surgical procedures for some other purpose or at cadaveric dissection, but sometimes can cause neurovascular compressions and may mimic neuroma or soft tissue tumours. Variations in different muscles of forearm flexors have been described by various authors. Variations like anomalous accessory palmaris longus, anomalous flexor digitorum superficialis indicis, palmaris brevis profundus, abductor digiti minimi longus, anomalous muscle belly of the flexor digitorum superficialis have been found by different investigators (Vichare, 1970; Roberts, 1972; Kernohan et al., 1984; Ametewee et al., 1985; Elias and Schuller-Ellis, 1985; Tonkin and Lister, 1985; Lahey and Alicino, 1986; Kostka and Steen, 1990). Palmaris longus and flexor carpi ulnaris muscles are common to exhibit variations in forearm (Kunc et al., 2019; Pires et al., 2019). Also, presence of accessory flexor carpi ulnaris has been reported by some authors. These variations are usually asymptomatic but can also involve neurovascular structures and symptoms can also mimic carpal tunnel syndrome. One such rare accessory muscle of forearm is described in this report. Presence of these variations should be ruled out early in cases of neurovascular compressions for better prognosis and management. These can also be considered as an option for tendon grafts and muscle flaps.

## Case report

During routine dissection for undergraduate teaching, an unusual variation involving flexor carpi ulnaris (FCU) and palmaris longus (PL) was found in the left forearm. A muscle was originating from the distal part of both FCU and PL through a slip from each tendon (2 slips). The 2 slips fused together, extended for some distance and finally their fibers merged with the proximal part of hypothenar muscle (flexor digiti minimi brevis) by passing under the volar carpal ligament but above the carpal ligament. Passive pull to this muscle caused flexion at fifth metacarpophalangeal joint. This muscle was forming the roof of Guyon's canal. Ulnar nerve and artery were running deep to this muscle. This strip of muscle was supplied by the ulnar artery and innervated by the ulnar nerve (Figure 1). This muscle did not have any tendinous sheath. Dimensions (length and width in centimetres) of slips from PL and FCU were  $2.3 \times 0.9$  and  $3.5 \times 1.3$  respectively. Length and maximum width of common slip was 6.2 cm and 2.8 cm respectively. No variation was found in flexor compartment of right forearm.

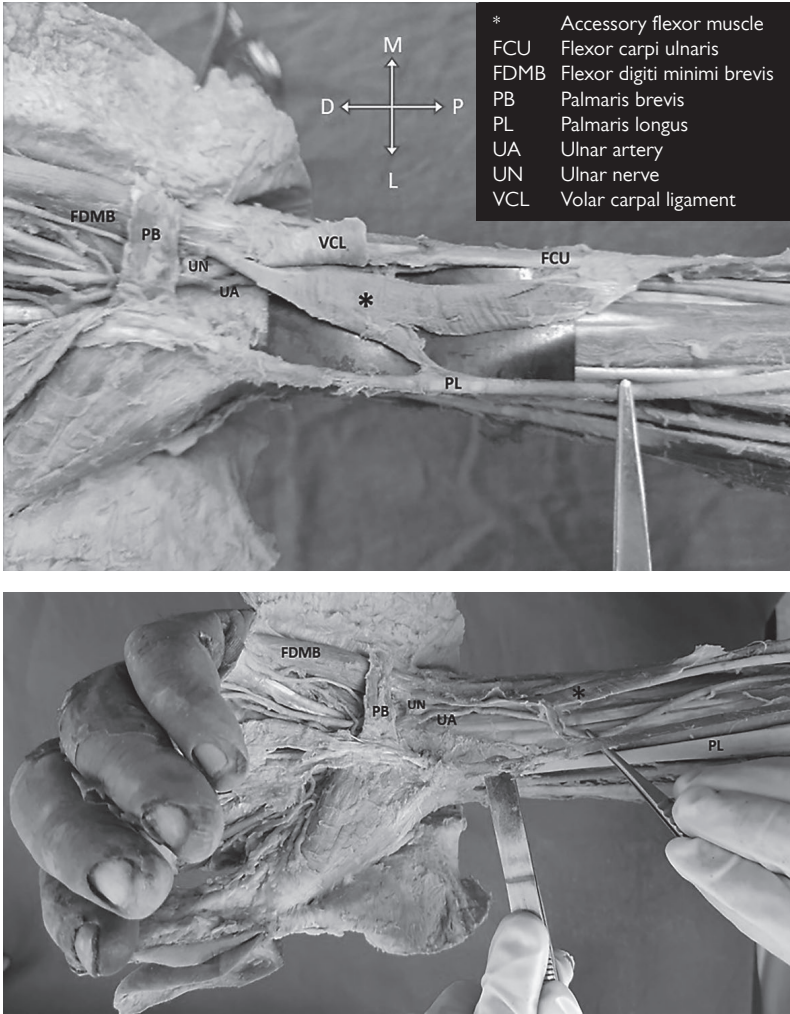


Figure 1 – Accessory flexor muscle in left forearm.

## Discussion

A number of supernumerary or accessory muscles have been described in flexor aspect of forearm. These variations mainly involve palmaris longus, flexor digitorum profundus (FDP), and flexor carpi ulnaris. Accessory slips to FDP have been found to be originating from radius, coronoid process of ulna, medial epicondyle, flexor digitorum superficialis and flexor pollicis longus (Bergman et al., 1988; Williams et al., 1995). Aberrant pollicis longus tendon passing through Guyon's canal have been described by Still and Kleinert (1973). Absence of PL tendon with presence of

**Table 1 – Reported palmaris longus and flexor carpi ulnaris variations**

<b>Palmaris longus variations</b>	Absence	Yammine (2013) Kigera and Mukwaya (2011) Kapoor et al. (2008) Sebastin et al. (2005) Ceyhan and Mavt (1997) Troha et al. (1990)	
	Digastric	Macalister (1875)	
	Duplication	Georgiev et al. (2009) Mori (1964) Reimann et al. (1944)	
	Reversed	Longhurst et al. (2020) Georgiev and Jeleu (2009) Depuydt et al. (1998) Ninković et al. (1995) Giunta et al. (1993) Meyer and Pflaum (1987)	
	Bifid/trifid	Natsis et al. (2007)	
	Intermediate belly	Kachlik et al. (2016)	
	Palmaris accessories	Mori (1964) Macalister (1875)	
	Palmaris profundus	Dyreby and Engber (1982)	
	Inserted at the base of 4 <sup>th</sup> middle phalanx	Bernardes et al. (2016)	
	Accessory palmaris longus	Yuan et al. (2019)	
	<b>Flexor carpi ulnaris variations</b>	A-FCU	Wang and Ng (2021) Kunc et al. (2019) Pires et al. (2019) Alvin et al. (2011) Ang et al. (2010) Vollala and Kumar (2007) Bergman et al. (1988) Testut and Latarjet (1928)
		Split insertion of FCU tendon	al-Qattan and Duerksen (1992) O'Harra and Stone (1988)
		Two heads as two separate bellies and joined into a tendon proximal to wrist	Rao et al. (2009)
Anomalous conjoined FCU and palmaris longus with bifid head insertion		Lemon and Belcher (2002)	

FCU – flexor carpi ulnaris

accessory abductor digiti minimi tendon have also been described (Jeffery, 1971). Solitary absence of PL tendon has been described by many authors (Kigera and Mukwaya, 2011; Yammine, 2013). Reversed, bifid/trifid bellies and intermediate belly

of PL have also been found by different authors (Kachlik et al., 2016; Longhurst et al., 2020). Presence of accessory FCU has also been described in literature. Different origins and insertions for the accessory flexor carpi ulnaris have been described (Kunc et al., 2019; Wang and Ng, 2021). All the variations related to palmaris longus and flexor carpi ulnaris muscle described earlier have been tabulated (Table 1). Accessory muscle found in our case is totally different from the existing literature.

Embryologically, muscles develop from paraxial (myogenic and connective tissue cells) mesoderm (Buckingham et al., 2003; Schoenwolf et al., 2014; Sefton and Kardon, 2019). Different segments of paraxial mesoderm form somites, which consist of two parts; sclerotome giving rise to bones and cartilages of vertebral column and thoracic cage, and dermomyotome giving rise to muscles and dermis of skin. Myoblasts originating from myotomes migrate to form limb muscles in fifth week of intrauterine life. After migration, they condense differently in ventral and dorsal aspect of forearm giving rise to muscles of that compartment (Buckingham et al., 2003; Schoenwolf et al., 2014). Final appearance of muscles depends upon some growth factors released at the time of differentiation and apoptotic mechanisms. MyoD, Myf5 and Mrf4 are important myogenic growth regulatory factors. Muscle connective tissue (MCT) fibroblasts, which develop from lateral plate mesoderm are crucial regulators of muscle development (Asfour et al., 2018; Sefton and Kardon, 2019). Four fundamental phases have been described in the ontogenesis of muscle patterns. The presence of supernumerary/accessory muscle could be regarded to originate at phase 3 when different layers of muscle primordia fuse to form muscle proper (Čihák, 2013). Also, defect in any process of muscle development like migration, fusion, displacement, and apoptosis could lead to origin of these type of accessory muscles. Finally, defect in action of growth factors and apoptotic factors could also lead to abnormal development of muscles.

Similar variation mimicking present case have not been found previously. But slight similarity like accessory FCU was reported. Anthropologically, these type of aberrant origin or insertion of forearm muscles were found in animals. Absence of ulnar slip of FCU was found in pigs. In tapir (*Tapiridae tapirus*), ulnar slip of FCU was found to be fibrous in nature (Le Double, 1897). Also, fusion of proximal part of FCU with PL was found in rats (Diogo et al., 2009). Bifurcation of FCU tendon was found in dogs (Kuan et al., 2007). Variabilities in muscles of forearm show similarities with cases found in other mammals and animals of other species.

Variation in muscles of forearm is not only important from anatomical, embryological, and anthropological point of view; it is also relevant clinically. Variation found in present case can cause compression of ulnar nerve and vessels in region of Guyon's canal (Vanhoenacker et al., 2018; Pires et al., 2019). Also, ulnar artery thrombosis has been found to be associated with abnormal muscle in Guyon's canal (Pribyl and Moneim, 1994). As, these muscles can mimic soft tissue masses

or tumours in this region with similar clinical symptoms and signs; knowledge about these will add to proper diagnosis and management. Surgical exploration in forearm and hand surgery may pose confusion sometimes if abnormal muscle variations are present in relation to important nerves and vessels. Therefore, differences in incidence of abnormal or accessory muscles in forearm should be evaluated and kept in mind during any diagnostic or surgical intervention in this region. These accessory muscles can also be used as free muscle flaps in reconstructive surgeries (Kreulen and Smeulders, 2008; Metikala et al., 2020). It provides a useful option to do reconstruction without compromising normal functioning of hand (Lim et al., 2006; Shen et al., 2008). In case of nerve compression, knowledge of variant anatomy with presence of an accessory muscle in this region becomes important to accurately diagnose the cause and treat accordingly.

## Conclusion

Presence of accessory flexor muscles of forearm can cause neurovascular compression and can mimic as soft tissue masses or tumours or neuromas. Proper knowledge about these will be important for accurate diagnosis and management of neurovascular compression caused by a vast number of pathologies. Also, these can be used in muscle flap or tendon transfer surgeries in hand or other regions. So, reporting such cases is important to further expand anatomical and surgical knowledge.

## References

- al-Qattan, M. M., Duerksen, F. (1992) A variant of flexor carpi ulnaris causing ulnar nerve compression. *J. Anat.* **180(Pt 1)**, 189–190.
- Alvin, M., Alan, N., Leone, J., Fredieu, J. R. (2011) A unilateral accessory flexor carpi ulnaris muscle observed during cadaveric dissection. *Clin. Anat.* **24(8)**, 971–973.
- Ametewee, K., Harris, A., Samuel, M. (1985) Acute carpal tunnel syndrome produced by anomalous flexor digitorum superficialis indicis muscle. *J. Hand Surg. Br.* **10(1)**, 83–84.
- Ang, G. G., Rozen, W. M., Vally, F., Eizenberg, N., Grinsell, D. (2010) Anomalies of the flexor carpi ulnaris: Clinical case report and cadaveric study. *Clin. Anat.* **23**, 427–430.
- Asfour, H. A., Allouh, M. Z., Said, R. S. (2018) Myogenic regulatory factors: The orchestrators of myogenesis after 30 years of discovery. *Exp. Biol. Med. (Maywood)* **243(2)**, 118–128.
- Bergman, R. A., Thompson, S. A., Afifi, A. K., Saadeh, F. A. (1988) *Compendium of Human Anatomic Variation*. Urban and Schwarzenberg, Baltimore.
- Bernardes, A., Melo, C., Pinheiro, S. (2016) A combined variation of palmaris longus and flexor digitorum superficialis: Case report and review of literature. *Morphologie* **100(331)**, 245–249.
- Buckingham, M., Bajard, L., Chang, T., Daubas, P., Hadchouel, J., Meilhac, S., Montarras, D., Rocancourt, D., Relax, F. (2003) The formation of skeletal muscle: From somite to limb. *J. Anat.* **202(1)**, 59–68.

- Ceyhan, O., Mavt, A. (1997) Distribution of agenesis of palmaris longus muscle in 12 to 18 years old age groups. *Indian J. Med. Sci.* **51(5)**, 156–160.
- Čihák, R. (2013) *Ontogenesis of the Skeleton and Intrinsic Muscles of the Human Hand and Foot*. Springer, Berlin, Heidelberg.
- Depuydt, K. H., Schuurman, A. H., Kon, M. (1998) Reversed palmaris longus muscle causing effort-related median nerve compression. *J. Hand Surg. Br.* **23(1)**, 117–119.
- Diogo, R., Abdala, V., Aziz, M. A., Lonergan, N., Wood, B. A. (2009) From fish to modern humans – Comparative anatomy, homologies and evolution of the pectoral and forelimb musculature. *J. Anat.* **214(5)**, 694–716.
- Dyreby, J. R., Engber, W. D. (1982) Palmaris profundus – Rare anomalous muscle. *J. Hand Surg. Am.* **7(5)**, 513–514.
- Elias, L. S., Schuller-Elias, F. P. (1985) Anomalous flexor superficialis indicis: Two case reports and literature review. *J. Hand Surg. Am.* **10(2)**, 296–299.
- Georgiev, G. P., Jeleu, L. (2009) Unusual coexistence of a variant abductor digiti minimi and reversed palmaris longus and their possible relation to median and ulnar nerves entrapment at the wrist. *Rom. J. Morphol. Embryol.* **50(4)**, 725–727.
- Georgiev, G. P., Jeleu, L., Surchev, L. (2009) Presence of a palmaris longus related variations in three members of a family. *J. Hand Surg. Eur. Vol.* **34(2)**, 277–278.
- Giunta, R., Brunner, U., Wilhelm, K. (1993) Bilateral reversed palmaris longus muscle – A rare cause of peripheral median nerve compression syndrome. Case report. *Unfallchirurg* **96(10)**, 538–540. (in German)
- Jeffery, A. K. (1971) Compression of the deep palmar branch of the ulnar nerve by an anomalous muscle: Case report and review. *J. Bone Joint Surg. Br.* **53(4)**, 718–723.
- Kachlik, D., Hajek, P., Konarik, M., Krchov, M., Baca, V. (2016) Coincidence of superficial brachiomedian artery and bitendinous palmaris longus: A case report. *Surg. Radiol. Anat.* **38**, 147–151.
- Kapoor, S. K., Tiwari, A., Kumar, A., Bhatia, R., Tantuway, V., Kapoor, S. (2008) Clinical relevance of palmaris longus agenesis: Common anatomical aberration. *Anat. Sci. Int.* **83(1)**, 45–48.
- Kernohan, J., Dakin, P. K., Quain, J. S., Helal, B. (1984) An anomalous flexor digitorum superficialis indicis muscle in association with a fibroma presenting as a stiff painful finger. *J. Hand Surg. Br.* **9(3)**, 335–336.
- Kigera, J. W., Mukwaya, S. (2011) Frequency of agenesis palmaris longus through clinical examination – An East African study. *PLoS One* **6(12)**, e28997.
- Kostka, K. H., Steen, M. (1990) The abductor digiti minimi longus muscle as a cause of distal ulnar compression syndrome. *Handchir. Mikrochir. Plast. Chir.* **22(1)**, 53–54. (in German)
- Kreulen, M., Smeulders, M. J. (2008) Assessment of flexor carpi ulnaris function for tendon transfer surgery. *J. Biomech.* **41(10)**, 2130–2135.
- Kuan, S. Y., Smith, B. A., Fearnside, S. M., Black, A. P., Allan, G. S. (2007) Flexor carpi ulnaris tendonopathy in a Weimaraner. *Aust. Vet. J.* **85(10)**, 401–404.
- Kunc, V., Stulpa, M., Feigl, G., Kachlik, D. (2019) Accessory flexor carpi ulnaris muscle with associated anterior interosseous artery variation: Case report with the definition of a new type and review of concomitant variants. *Surg. Radiol. Anat.* **41**, 1315–1318.
- Lahey, M. D., Aulicino, P. L. (1986) Anomalous muscles associated with compression neuropathies. *Orthop. Rev.* **15(4)**, 199–208.
- Le Double, A. F. (1897) *Traité des Variations du Système Musculaire de L'homme: Et de Leur Signification au Point de Vue de L'anthropologie Zoologique*, Vol. 2. Schleicher frères, Paris.
- Lemon, M., Belcher, H. J. (2002) An anomalous flexor carpi ulnaris. *J. Hand Surg. Br.* **27(2)**, 194–197.
- Lim, A. Y., Kumar, V. P., Sebastin, S. J., Kapickis, M. (2006) Split flexor carpi ulnaris transfer: A new functioning free muscle transfer with independent dual function. *Plast. Reconstr. Surg.* **117(6)**, 1927–1932.

- Longhurst, G., Stone, D., Mahony, N. (2020) Bilateral reversed palmaris longus muscle: A case report and systematic literature review. *Surg. Radiol. Anat.* **42**, 289–295.
- Macalister, A. (1875) Additional observations on muscular anomalies in human anatomy (third series), with a catalogue of the principal muscular variations hitherto published. *Trans. Roy. Irish Acad. Sci.* **25**, 1–134.
- Metikala, S., Mohammed, R., Vakamalla, V. R. (2020) Clinical application of anomalous muscles for tendon transfer in the upper limb: A systematic review of the literature. *Cureus* **12(3)**, e7222.
- Meyer, F. N., Pflaum, B. C. (1987) Median nerve compression at the wrist caused by a reversed palmaris longus muscle. *J. Hand Surg. Am.* **12(3)**, 369–371.
- Mori, M. (1964) Statistics on the musculature of the Japanese. *Okajimas Folia Anat. Jpn.* **40**, 252–254.
- Natsis, K., Levva, S., Totlis, T. (2007) Three-headed reversed palmaris longus muscle and its clinical significance. *Ann. Anat.* **189(1)**, 97–101.
- Ninković, M., Hefel, L., Öhler, K. (1995) Acute median nerve compression produced by reversed palmaris longus muscle. *Eur. J. Plast. Surg.* **18**, 129–130.
- O'Hara, J. J., Stone, J. H. (1988) Ulnar neuropathy at the wrist associated with aberrant flexor carpi ulnaris insertion. *J. Hand Surg. Am.* **13(3)**, 370–372.
- Pires, L. A. S., Machado, G. D. C. R., Fernandes, R. M. P., Manaia, J. H. M., Champs, J. F. S., Babinski, M. A. (2019) Notes on the accessory flexor carpi ulnaris muscle: A rare supernumerary variation. *J. Morphol. Sci.* **36(02)**, 138–140.
- Pribyl, C. R., Moneim, M. S. (1994) Anomalous hand muscle found in the Guyon's canal at exploration for ulnar artery thrombosis: A case report. *Clin. Orthop. Relat. Res.* **306**, 120–123.
- Rao, K. G., Bhat, S. M., Venkataramana, V., Rodrigues, V. (2009) Ulnar and humeral heads forming separate bellies: A rare case of digastric flexor carpi ulnaris muscle. *Int. J. Morphol.* **27(1)**, 31–34.
- Reimann, A. F., Daseler, E. H., Anson, B. J., Beaton, L. E. (1944) The palmaris longus muscle and tendon. A study of 1600 extremities. *Anat. Rec.* **89(4)**, 495–505.
- Roberts, P. H. (1972) An anomalous accessory palmaris longus muscle. *Hand* **4(1)**, 40–41.
- Schoenwolf, G. C., Bleyl, S. B., Brauer, P. R., Francis-West, P. H. (2014) *Larsen's Human Embryology*. Elsevier Health Sciences, Amsterdam.
- Sebastin, S. J., Puhaindran, M. E., Lim, A. Y., Lim, I. J., Bee, W. H. (2005) The prevalence of absence of the palmaris longus – A study in a Chinese population and a review of the literature. *J. Hand Surg. Br.* **30(5)**, 525–527.
- Sefton, E. M., Kardon, G. (2019) Connecting muscle development, birth defects, and evolution: An essential role for muscle connective tissue. *Curr. Top. Dev. Biol.* **132**, 137–176.
- Shen, S., Pang, J., Seneviratne, S., Ashton, M. W., Corlett, R. J., Taylor, G. I. (2008) A comparative anatomical study of brachioradialis and flexor carpi ulnaris muscles: Implications for total tongue reconstruction. *Plast. Reconstr. Surg.* **121(3)**, 816–829.
- Still, J. M. Jr., Kleinert, H. E. (1973) Anomalous muscles and nerve entrapment in the wrist and hand. *Plast. Reconstr. Surg.* **52(4)**, 394–400.
- Testut, L., Latarjet, A. (1928) *Traite D'anatomie Humaine*, 8<sup>th</sup> Edition. Gaston Douin, Paris.
- Tonkin, M. A., Lister, G. D. (1985) The palmaris brevis profundus. An anomalous muscle associated with ulnar nerve compression at the wrist. *J. Hand Surg. Am.* **10(6 Pt 1)**, 862–864.
- Troha, F., Baibak, G. J., Kelleher, J. C. (1990) Frequency of the palmaris longus tendon in North American Caucasians. *Ann. Plast. Surg.* **25(6)**, 477–478.
- Vanhoenacker, F. M., Desimpel, J., Mespreuve, M., Tagliafico, A. (2018) Accessory muscles of the extremities. *Semin. Musculoskelet. Radiol.* **22(3)**, 275–285.
- Vichare, N. A. (1970) Anomalous muscle belly of the flexor digitorum superficialis. Report of a case. *J. Bone Joint Surg. Br.* **52(4)**, 757–759.



- Vollala, V. R., Kumar, P. B. (2007) Additional belly of flexor carpi ulnaris muscle found in a South Indian male cadaver. *Internet J. Orthop. Surg.* **5(1)**, 5–8.
- Wang, C. K., Ng, C. Y. (2021) Accessory flexor carpi ulnaris: A rare cause of distal ulnar nerve compression. *J. Hand Surg. Eur. Vol.* **46(2)**, 197–199.
- Williams, P., Bannister, L., Berry, M., Collins, P., Dyson, M., Dussek, J. (1995) *Gray's Anatomy: The Anatomical Basis of Medicine and Surgery*, 38<sup>th</sup> Edition. Churchill Livingstone, Edinburgh.
- Yamine, K. (2013) Clinical prevalence of palmaris longus agenesis: A systematic review and meta-analysis. *Clin. Anat.* **26(6)**, 709–718.
- Yuan, J., Dhanaraj, I. D., Ng, H. J. H., Rajaratnam, V. (2019) Accessory palmaris longus: A concise anatomic review with a relevant case study. *Ann. Plast. Surg.* **83(3)**, 363–366.